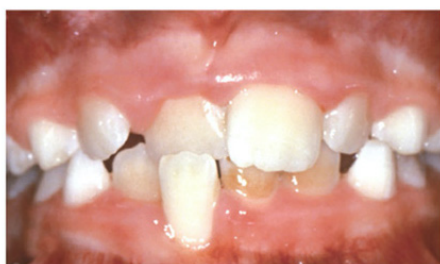
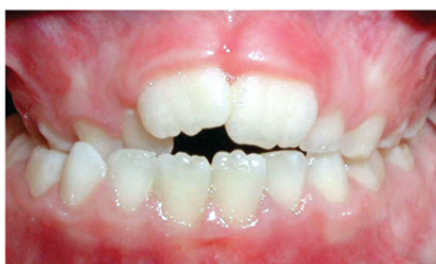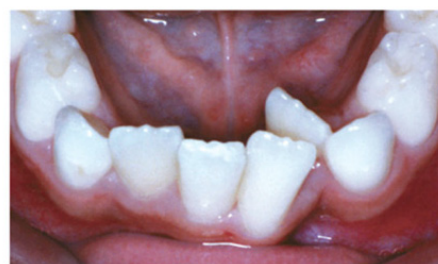Problems to Watch for in Seven Year Olds



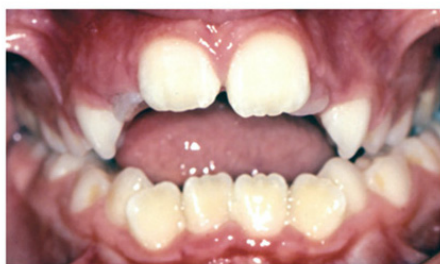Anterior Crossbite



Posterior Crossbite

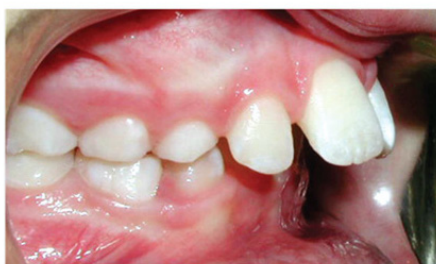

Crowding

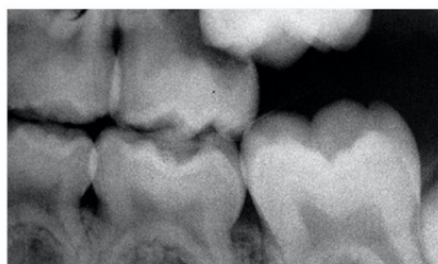

Open Bite

An open bite is usually due to an oral habit.

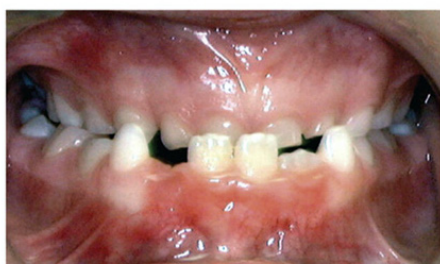

Protrusion

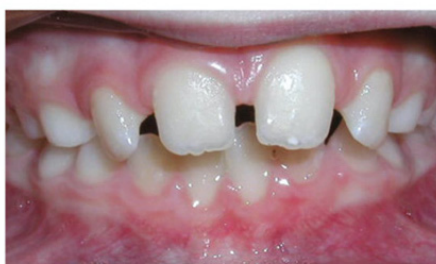

Ectopic Eruption

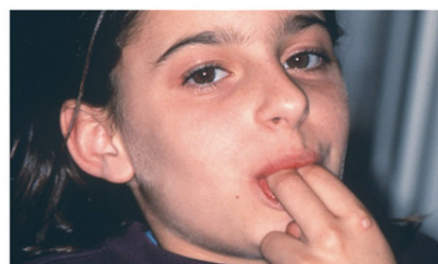
Ectopically erupting maxillary molar.



Complete Class III



Diastema



Oral Habits

Malocclusions, like those illustrated above, may benefit from early diagnosis and referral to an orthodontic specialist for a full evaluation.
